

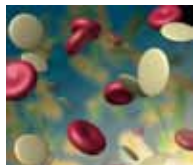IMPLANT TRIBUNE

The World's Dental Implant Newspaper · U.S. Edition

NOVEMBER 2009

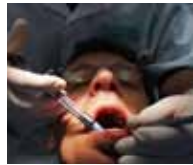www.implant-tribune.com

VOL. 4, No. 11



Platelet-rich plasma
PRP therapy can accelerate bone and tissue growth

▶Page 2



Implant experiences
Success rests on your interaction with the patient

▶Page 11



New implant products
Implant system has many options, a variety of pricing

▶Page 22

The forgotten implant: subperiosteal

By Pankaj Singh, DDS, DICOI, DABOI, FAAID

With very advanced jawbone resorption, there may not be enough bone width or height for the more common and routinely placed type of implant: the root form implant.

This advanced, severe bone resorption is due to long-standing edentulism and the detrimental forces from loading these jaws with soft-tissue supported dentures.

One complication that arises from this severe bone resorptive pattern is ill-fitting dentures that even after repeated relines aren't stable during normal or even soft mastication and the patients have to use massive amounts of denture adhesive to just keep them in place to speak.

Besides being a quality of life issue, it becomes a health issue as the lack of proper masticatory process results in inadequate nutrition, which leads to a host of digestive disorders including acid reflux and esophageal blockage, and can even contribute to metabolic disorders¹. Chronic excessive use of denture cream containing zinc may result in hypocupremia and serious neurologic disease.²⁻⁴

Another major complication is pain from direct pressure on the exposed inferior alveolar nerve a

→ [page 4](#)

AAID covers it all in New Orleans

By Sierra Rendon, Managing Editor

From implant design to emergency medicine to particulate grafting, there was in-depth information for everyone to take home with them from the American Academy of Implant Dentistry meeting, which was held Nov. 11 to 14 in New Orleans.

The meeting offered three days of education on new techniques on a wide variety of subjects.

Here is a sampling of the meeting's topics:

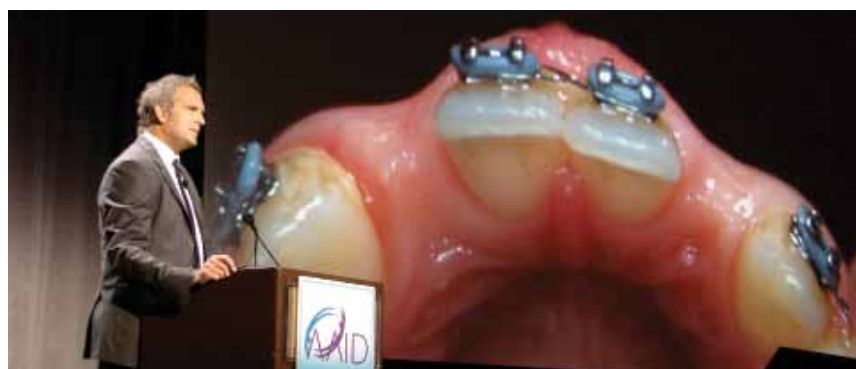***New implant design:** Drs. Henry Salama, Maurice Salama and David Garber presented from the perspective that implant-supported restoration must cosmetically equal or surpass that of conventional restorative dentistry.

They outlined the biological, clinical and biomechanical factors that allow clinicians to reduce or eliminate the waiting period to implant loading without sacrificing predictably successful osseointegration.

Emergency medicine: Dr. Stanley Malamed presented a dynamic pro-

Photo Gallery, Page 15

→ [page 14](#)



Above, Dr. Eric Van Dooren speaks Nov. 12 on the main podium. Below, Alex Miller, president of Meisinger, talks with AAID attendees about products. (Photos/Sierra Rendon)



AD

AUXILIARIES: Are you implant certified?

Patient Questions... Insurance Coverage... Tracking...
Operator Set Up... Radiographic Protocol...
Assessment Parameters... Hygiene Instrumentation...
Communications with the Lab...

Implant Training Makes all the Difference!

Dental Hygiene Implant Certification Program® (DHICP) • Practice Management Implant Certification Program® (PMICP)

Dental Assisting Implant Certification Program® (DAICP) • Implant Coordinator Training Program®

The ADIA presents these comprehensive courses at many venues throughout the year.



To find out more about these exciting programs and about membership in the ADIA visit our website:

www.adiaonline.org

PRSRT STD
U.S. Postage
PAID
Permit # 306
Mechanicsburg, PA

Dental Tribune America
213 West 35th Street
Suite #801
New York, NY 10001

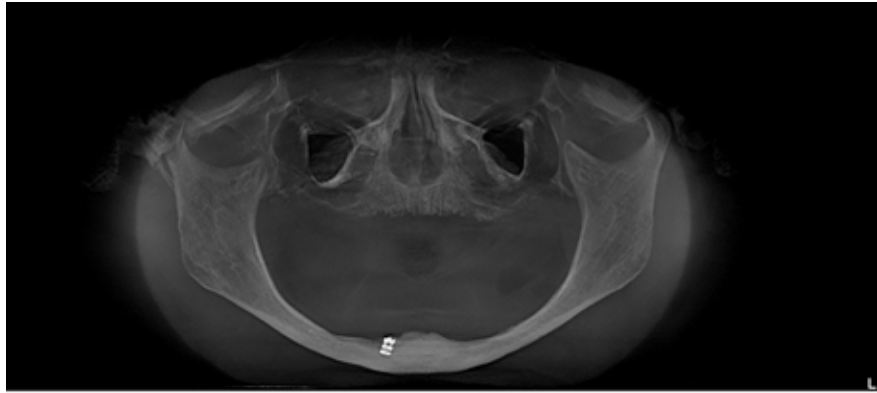


Fig. 1: Panoramic view of a severely resorbed mandible.



Fig. 2a: Mandibular complete arch subperiosteal implant with locator attachments and countersunk screw holes for bone screws.



Fig. 2b: Maxillary subperiosteal implant with receptacles with thread pattern for locator abutments and countersunk screw holes for rigid fixation using bone screws.

← **ii** page 1

result of dehissed inferior alveolar canal and mental foramen by the mandibular denture and resulting Trigeminal neuralgia.⁵

In these cases the subperiosteal implant can be of tremendous help.

By definition, a subperiosteal implant is a framework specifically fabricated to fit the supporting areas of the mandible or maxilla with permucosal extensions for support and attachment of a prosthesis. The framework consists of permucosal extensions with or without connecting bars and struts. Struts are classified as peripheral, primary and secondary. The subperiosteal implant can be constructed as a complete arch, unilateral or universal, and is

loaded immediately.

Prior to the tremendous success of the root form implants since Dr. Brånemark introduced the concept of osseointegration in 1981, the subperiosteal implant along with blade and plate implants were routinely used to support either a fixed, or removable, complete or partial prosthesis. The subperiosteal implant is custom made and designed to fit and sit on top and around the bone, but under the gums. There are two methods for its fabrication and installation.

The first and original technique is the "dual surgery" method. Usually under sedation, the jawbone is exposed and an impression of the bone is made using a custom impression tray and the impression material of choice (not alginate).

Whenever possible, vertical dimension in centric relation to the alveolar ridge with the opposing arch to provide inter-maxillary distance for determination of abutment height of the subperiosteal framework and the height of the prosthesis is recorded while the bone was still exposed. The gums are sutured closed and the patient is dismissed with a facemask-type compression bandage.

This impression is poured with plaster to fabricate a replica (model) of the jawbone and the model is used by the dental laboratory to custom cast the implant with the suprastructure to fit the jaw along with the final prosthesis that was prescribed. Six to eight weeks after the first-stage "impression acquisition" surgery, a second procedure is then carried out

where the jawbone is re-exposed and the implant placed and secured into place. The gums are closed with stitches over the subperiosteal and around the suprastructures and the prosthesis is placed into place.

This type of protocol was very common and predictable as it used very familiar and commonly practiced prosthodontic techniques for workup and fabrication of the implant and the final prosthesis, but was very unsatisfactory to the patient and a big deterrant for undergoing the therapy.

In the late 1980s and early 1990s with CT and within the past decade cone beam volumetric tomographic (CBVT) scans becoming more common in dental/oral surgical diag-

→ **ii** page 6

AD

Benex[®] - Control Professional

Root Extraction Systems developed with Dr. Syfrig



- Safe and simple extraction of roots
- Maximal protection of the tooth socket
- Possibility of drilling even if minute root fragments or foreign bodies are present in the root
- Possibility of drilling independently of anatomic root canal

MEISINGER

GERMANY / USA





MEISINGER USA, L.L.C.
 7442 South Tucson Way • Suite 130 • Centennial • Colorado 80112 • USA
 Tel.: +1 (303) 268-5400 • Fax: +1 (303) 268-5407 • E-Mail: info@meisingerusa.com
 www.meisingerusa.com • www.bone-management.com • www.occlusalrouter.com

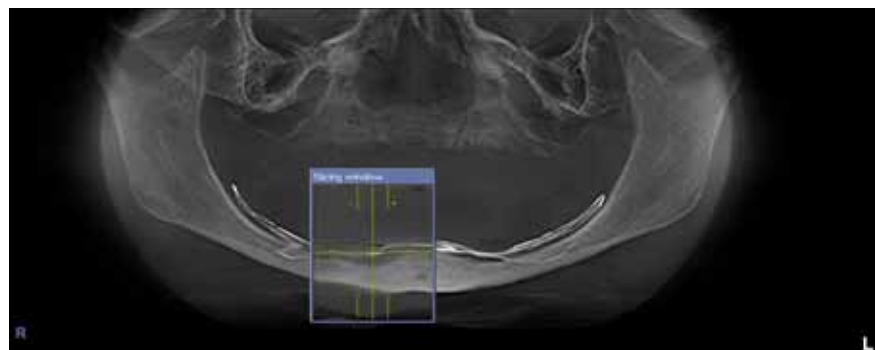


Fig. 3a: Panoramic.

← **ii** page 4

nosis and treatment planning, and medical modeling companies getting better and more accurate in computer modeling of anatomic structures, the first stage surgery for the fabrication of an accurate impression of the jaw was bypassed.

For the “single surgery” method, a special CT/CBVT scan of the arch being considered for rehabilitation is ordered. A replica (radiographic template) of the final prosthesis is fabricated with the denture base made with acrylic with 25 percent barium sulfate, a radiopaque marker that shows in the 3-D radiograph outlining the soft tissue (gum) architecture (Fig. 3).

The radiographic template is

worn during the scan, and using the scan data and advanced computer modeling techniques, a model of the jawbone and overlaying soft tissue is constructed.

This stereoithographic model (Fig. 4) of the alveolus and the overlaying gum (Fig. 5) is used by the dental laboratory to fabricate the custom subperiosteal implant and process and finish the prosthesis for immediate function.

A surgical procedure is then carried out where the alveolus is exposed and the implant placed and secured to the jaw (with bone screws) and any gaps between the implant and the underlying bone is filled with hard tissue graft of the dentist’s liking and guided bone regeneration technique is applied. The gums are closed with stitches

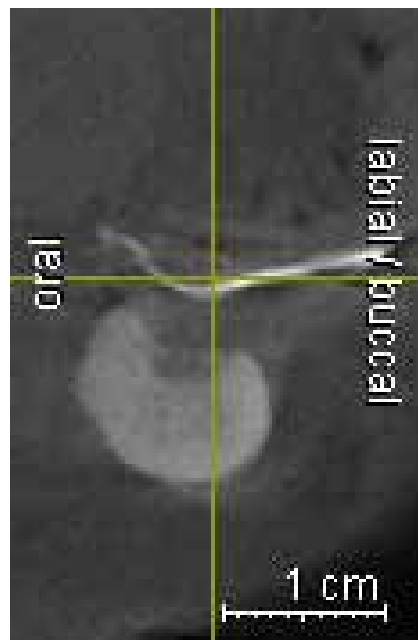


Fig. 3b: Cross-section view of the radiopaque radiographic guide; notice the dehissed mental foramen.



Fig. 4a: Mandibular model with the subperiosteal over it in place.



Fig. 4b: Maxilla, occlusal view.



Fig. 4b: Maxilla, anterior view.

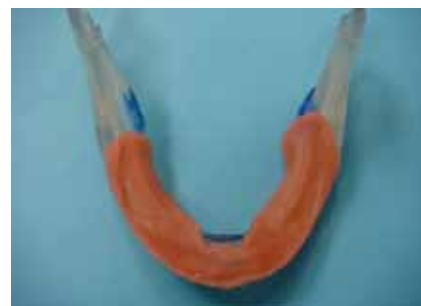

Fig. 5a: Mandible.

and the prosthetic is put into place for immediate function.

The patient is instructed in the usual manner for postoperative wound and prosthesis care and a stretchable compression bandage is applied.

This modern one-stage protocol is more palatable for the patient who is more likely to consider this form of implant therapy versus undergoing multiple augmentation procedures to build the ridge to the appropriate dimensions (height and width) in the certain areas for implantation of appropriately sized rootform implants. Depending on the location and type of materials used for augmentation, it could be six months to up to two years or more before the patient is rehabilitated with a final prosthesis.

At times, the patient is not a good candidate to undergo such significant augmentative procedures either due to health or financial considerations.

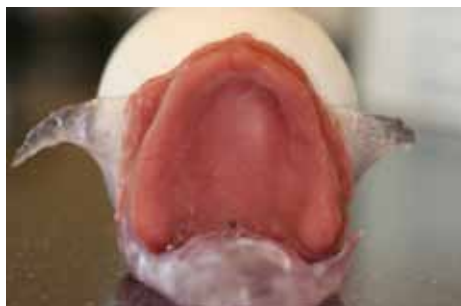

Fig. 5b: Maxilla.

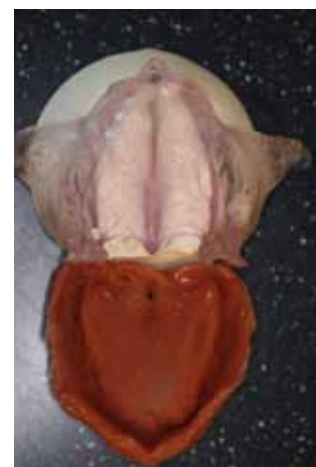




Fig. 5c: Maxilla degloved.


ADS

ANEW[®] NARROW-body implants

HANDS-ON WORKSHOP

DESIGNED TO FIT where **no** other can



Conventional fixtures, a predictable clinical standard, continue to exclude a wide range of patients with insufficient bone, narrow spaces and converging roots.

Reserve your space for the first HOW™ Hands-on Workshop in New Orleans & learn in real-time on an esthetic model how Anew Narrow-Body Implants overcome these challenges, with affordable remedies for the largest number of patient’s immediate needs.

To register, or for more information, call Dentatus (800) 323-3136.

December 9th - New Orleans, LA

© 2009 Dentatus USA, Ltd - Patented & Patents pending - Photos courtesy of New York University Dental Center

Dental Collab BETA

FINALLY A SOLUTION FOR GETTING THAT SECOND OPINION.

WWW.DENTALCOLLAB.COM

FIRST MONTH FREE

CODE: ITDC09



Case report No. 1

A 61-year-old caucasian female presents with the chief complaint that her lower denture doesn't fit well and every time she wore it, it caused great pain and a burning sensation in the lower jaw. She only wore it for cosmetic reasons and never chewed with them in and made excuses for not eating in company of others.

She has been to several dentists, including prosthodontists, who fail to fabricate complete removable mandibular dentures she can wear comfortably.

She also has sought consultations with several oral surgeons who would only recommend multiple autogenous onlay grafts in the intermental region for an implant-supported soft-tissue borne overdenture with the possibility of still experiencing pain due to the free end saddles pressing into the exposed mental foramen and inferior alveolar nerve when chewing.

Her past medical history was significant for post-menopausal osteoporosis for which she takes Boniva (ibandronate sodium) once a month. She also suffers from hypertension, which is under control, and for which she takes a combination of thiazide diuretic and beta blocker. She also suffers from panic disorder for which she takes Zanax (alprazolam) on a regular basis.

Social history is significant for her becoming a widow eight years ago and is socially active, and her only son was to be married within three months of consultation.

Her past dental history is significant for periodontal disease, which was the reason for her losing all of her teeth by the time she was in her 30s and now having severe atrophy of both jaws.

Twenty years ago, she began implant therapy for supporting her complete mandibular dentures. During the years, the implants failed for one reason or another and the last one remaining is fractured with a piece still integrated but not usable. Both mental foramen and parts of the mandibular canal are exposed on the crest of the alveolus with the nerves enveloped in the soft tissue over the crest.

Treatment plans were developed after an initial panoramic view was extracted from a CBVT.

Treatment plan No. 1

- Total treatment time: eight to 12 months.

- Anterior illiac crest to be used as a donor site for block grafts to augment the intermental region and posterior mandible with bilateral relocation of the mental foramen and mandibular canal more apically and laterally.

- Surgery under general anesthesia.

- Insertion of a full maxillary removable denture and immediate insertion complete mandibular denture at the time of mandibular augmentation.

- Healing time of six months and then insert four implants to support an implant-supported locator mandibular overdenture or eight implants to support a fixed cemented prosthesis and, depending on the primary



Fig. 6: Duplicate cast of the stereolithographic model with the waxup of the subperiosteal framework with locator abutments.

stability of the implants, to either load immediately or delay the load four months.

Treatment plan No. 2

- Total treatment time: six to eight weeks. (Patient elected to undergo

this option.)

- One-stage protocol mandibular subperiosteal (bone contact side coated with hydroxyl apatite) placement and rigid fixation with bone screws and simultaneous bilateral relocation of the mental foramen and mandibular canal more apically and laterally.

- Surgery under I.V. conscious sedation and local anesthesia.

- Insertion of a full maxillary removable denture and immediate insertion of a functionally loaded complete mandibular denture using four locator abutments.

- Permanent relining of the lower prosthesis in two months.

Case report No. 2

A 48-year-old caucasian female presents with the chief complaint that her lower implant bar-retained over-

denture is extremely uncomfortable, doesn't fit well and is cosmetically unacceptable. She is also unhappy with the way her maxillary denture fits and feels.

She has sought consultation from several dentists including prosthodontists, periodontists and oral surgeons who recommended various options, including removal of the existing implants and placing new ones in a more favorable angulation and even changing the retention mechanism from bar to individual implant retention (o-rings, locators and type).

For the maxillary denture, all recommended a new denture.

Her past medical history was insignificant.

→ page 8

AD

SimPlant[®] Crystal

Split-second sharpness

Sharp insights in the twinkling of an eye!

- Quick start your case planning with DentalPlanit[®] – 24/7 online collaboration with local imaging centers and other partners
- Obtain crystal clear images from CT and cone beam scanners

A must-have for your practice!

- Plan your case step by step, with ease and confidence
- Work with your preferred scanner and implant brands
- Communicate with your patients in a crystal clear way

3D Digital Dentistry
Allowing you to work in a more time and cost efficient environment

simple
compatible
unique

www.materialisedental.com

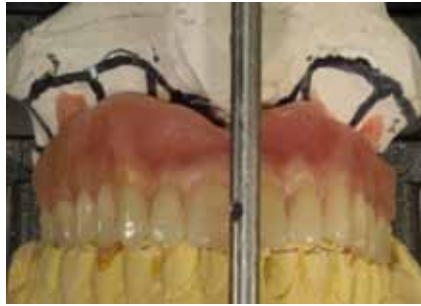

Fig. 7a: Processed final restoration; maxillary full denture.

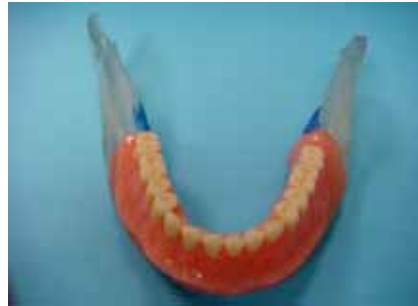

Fig. 7b: Processed final restoration; mandibular complete denture.

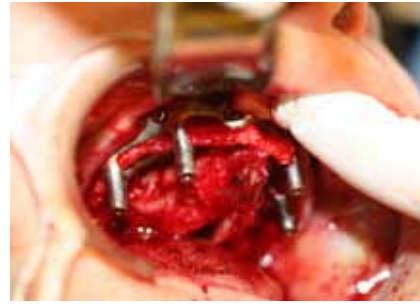

Fig. 8a: Subperiosteal over the maxillary ridge, held down with bone screws.



Fig. 8b: Bone screws and a mandibular subperiosteal.

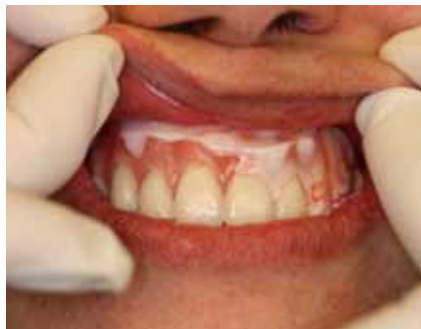

Fig. 9: Soft tissue reline of the immediately loaded maxillary denture.

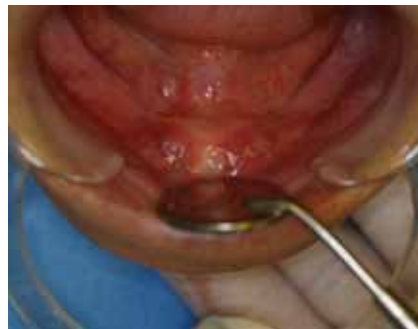

Fig. 10: Pre-op occlusal view of the severely resorbed mandible.

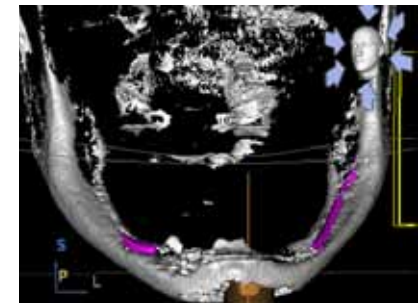


Fig. 11: Reconstructed view of the mandible with the exposed inferior alveolar canals highlighted in purple.

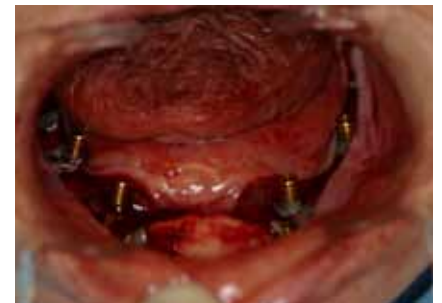

Fig. 12: Intraop view of the mandibular subperiosteal with bone screws visible on the buccal in the canine region.

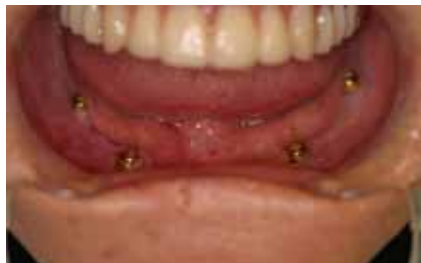

Fig. 13: Two weeks postoperative view of the transgingival locator abutments.

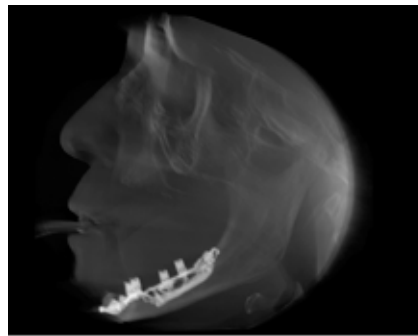


Fig. 14: Lateral Cephalometric view of the installed mandibular full subperiosteal implant. Notice the intimate fit of the framework to the underlying bone.

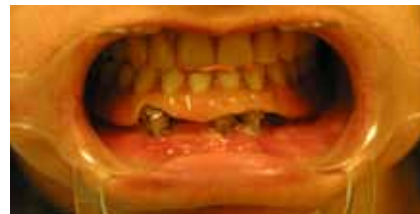

Fig. 15: Initial view of mandibular denture adapted to the implant-supported bar. Note the angulation of the implants, making the bar out too far labially where the buccal flange could not cover it, and a window cut out to accommodate the seating of the denture.

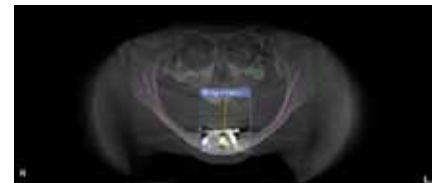

Fig. 16: Preoperative panoramic view outlining the mandibular canal in purple.

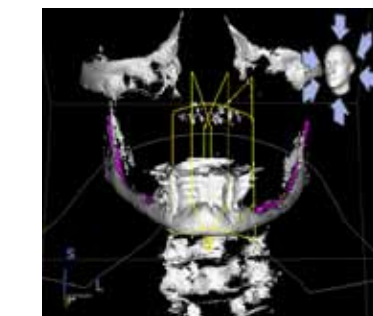


Fig. 17: Reconstructed 3-D view of the severely atrophied mandible and the maxilla with dehissed mandibular canals.

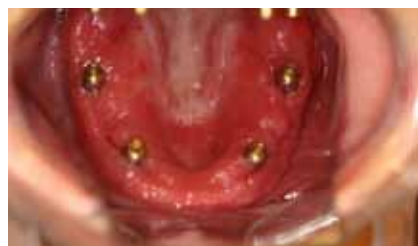

Fig. 18: One month postoperative view of the maxillary subperiosteal implant.

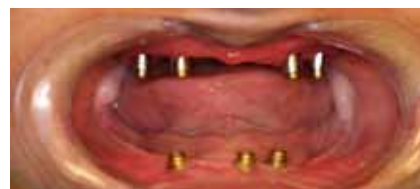

Fig. 19: Antero-posterior view of the permucosal locator abutment's part of the maxillary subperiosteal and the replacement of the mandibular bar for retention of complete dentures.

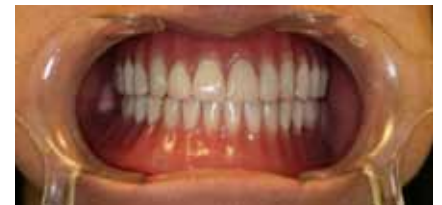

Fig. 20: Anterior view of the completed dentures in place, attached to the locator abutments.

← **11** page 7

nificant and was categorized as an ASA1 patient. Social history is significant for divorce five years ago, and she is planning on remarrying in the near future.

Her past dental history is significant for becoming completely edentulous at age 18 upon recommendation of her dentist. Ten years ago, she had four implants placed in the anterior mandibular symphysis out of which one failed. Her bar was preserved and made usable with three implants.

Two years ago, she had new mandibular and maxillary dentures fabricated by a prosthodontist that was recommended by the periodontist who removed the failed implant.

Treatment plans were developed after evaluation of the panoramic view extracted from the initial CBVT.

Treatment plan the patient elected to undergo: Total treatment time of eight to 12 weeks.

- Remove the mandibular anterior bar and replace it with locator abutments and fabricate a new mandibular implant-retained overdenture on the remaining three implants.

- One-stage protocol maxillary subperiosteal (bone contact side coated with hydroxyl apatite) placement and rigid fixation with bone screws.

- Surgery under I.V. conscious sedation and local anesthesia.

- Insertion of an immediate insertion (locator attached) complete maxillary denture at the time of implant placement.

Conclusion

Both patients and others like them have undergone this type of rehabilitation using subperiosteal implants without any untoward complications and have reported satisfactory results upon visits with the hygienist.

The author would like to acknowledge Dr. Jerome Kaufman, DDS, (prosthodontist) of Arch Dental at Le Visage Center for Cosmetic and

Implant Dentistry for performing the prosthetic workup and completion of such challenging reconstructions, and Ryan Dutton, CDT of Dutton Dental Laboratory, Ohio, for his exemplary fabrication of such difficult and precise frameworks..

For detailed step-by-step instructions on the protocol for a one- or two-stage subperiosteal implant and accompanying prosthetics, please refer to Chapters 14, 15, 26 of the "Atlas of Oral Implantology," third edition.

References

1. www.articlesbase.com/health-articles/do-you-use-tagamet-pepcid-axid-or-zantac-62586.html
2. M. Spinazzi and M. Armani, Neurology, July 7, 2009; 75(1):676.
3. Nations SP et al., Neurology 2008 Aug. 26; 71:639.
4. Schaumburg H and Herskovitz S., Neurology 2008 Aug. 26; 71:622.
5. L. R. Carney, Neurology, Dec. 1967; 17: 1143.

I About the author

Dr. Pankaj Singh has authored the third edition of the best-selling textbook on dental implants, "The Atlas of Oral Implantology," which will be released in December. Singh is an attending faculty at the Department of Dental Medicine and Oral Surgery at LIJ-North Shore University Hospital Medical Center in New York and is a clinical instructor of advanced dentistry at New York University College of Dentistry (subatinal). He is the founder and CEO of Arch Dental Associates and Le Visage Cosmetic & Implant Dentistry with offices in Manhattan, Huntington and Garden City, NY. Singh has been in private practice for more than 15 years, specializing in implant, sedation, reconstructive dentistry and dental sleep medicine. He is a graduate of New York University College of Dentistry. He completed his advanced training in dental implants at Brookdale Hospital and NYU.

